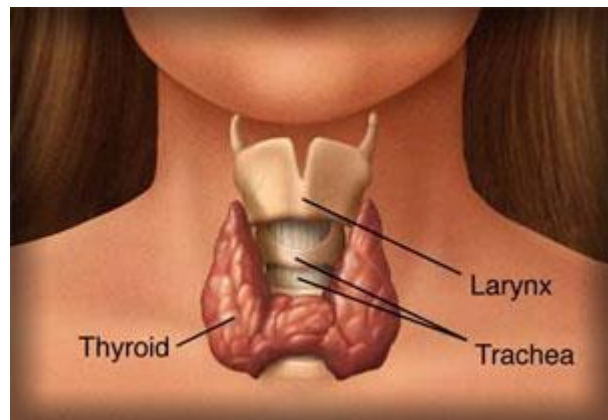


Introduction

Hürthle Cell Thyroid Cancer (Hürthle cell carcinoma and/or Hürthle cell adenoma) are usually classified with Follicular Thyroid Cancer, although it really is a distinct kind of tumour, making up about 3% of all thyroid cancer cases. It has a poor prognosis (outlook).

[Picture Credit: Thyroid]

A Hürthle Cell is a kind of thyroid cell that has a distinctive look: under the microscope it is bigger than a follicular cell and has pink-staining cellular material.



A Hürthle cell is a cell in the thyroid that is often associated with Hashimoto's thyroiditis as well as follicular thyroid cancer.

Hürthle Cell Carcinoma

Like follicular tumours, there are benign Hürthle cell tumours and malignant Hürthle cell tumours, and a pathologist can tell the difference between them based on invasion of the capsule and the blood vessels. Benign Hürthle cell tumours are not a threat at all and should not come back once they are removed.

Hürthle cell cancer is considered a variant of follicular thyroid cancer. This version is a relatively rare form of differentiated thyroid cancer, accounting for only 3-10% of all differentiated thyroid cancers.

Xu, B. & Ghossein, R. 2018.

“The vast majority of low grade follicular cell derived thyroid carcinomas follows an indolent clinical course and is associated with very low mortality. Risk stratification using multiple clinical and pathologic characteristics has become the standard of care to guide appropriate management and avoid overtreatment. Over the past few decades, the field of thyroid pathology has witnessed several major changes that significantly impacted upon patients' care. These are: 1) The reclassification of non-invasive encapsulated follicular variant of papillary thyroid carcinoma as noninvasive follicular thyroid neoplasm with papillary-like nuclear features; 2) the diagnosis of Hurthle cell carcinoma based on the presence of capsular and vascular invasion; 3) a detailed definition of poorly differentiated thyroid carcinoma, taking into consideration mitosis and necrosis; and 4) the emphasis on a detailed pathologic analysis such as the extent of vascular invasion and extrathyroidal extension. This review describes these histological concepts and details the history, rationale, and clinical impacts of such changes. These shifts in the classification and characterization of thyroid carcinoma provided a platform supporting therapy de-escalation. In addition several lessons were learned from these changes especially from the misclassification of the non-invasive encapsulated follicular variant of papillary thyroid carcinoma. We hope that the lessons learned will help better classify tumors in the future whether arising in the thyroid or other organs.”

Incidence of Hürthle Cell Carcinoma in South Africa

The National Cancer Registry (2016) does not provide any information on the incidence of Hürthle Cell Carcinoma in South Africa.

Symptoms of Hürthle Cell Carcinoma

Symptoms of Hürthle cell carcinoma are similar to those seen in other types of thyroid cancers.

Symptoms may include:

- Appearance of a lump at the neck
- Voice change that does not get better
- Shortness of breath
- Sore throat
- Difficulty in swallowing
- Persistent cough which is not caused by a respiratory problem

Hürthle Cell Carcinoma complications may include:

- Difficulty swallowing – when the tumour presses on the food pipe (oesophagus)
- Difficulty breathing – when the tumour presses on the windpipe (trachea)
- Spread of malignancy (metastasis) to other organs and tissues

Causes and Risk Factors for Hürthle Cell Carcinoma

It is not clear what causes Hürthle Cell Cancer.

Doctors know that cancer begins when a cell develops errors in its DNA - the genetic material that contains instructions for biochemical processes in one's body. When DNA is altered or damaged,

Researched and Authored by Prof Michael C Herbst

[D Litt et Phil (Health Studies); D N Ed; M Art et Scien; B A Cur; Dip Occupational Health; Dip Genetic Counselling; Dip Audiometry and Noise Measurement; Diagnostic Radiographer; Medical Ethicist]

Approved by Ms Elize Joubert, Chief Executive Officer [BA Social Work (cum laude); MA Social Work]

October 2020

these genes may not function properly, causing cells to grow out of control and eventually form a mass (tumour) of cancerous (malignant) cells.

Factors that may increase the risk of developing Hürthle Cell Cancer include:

- Being female
- Being older
- Having a history of radiation treatments to the head and neck

Gopal, R.K., Kübler, K., Calvo, S.E., Polak, P., Livitz, D., Rosebrock, D., Sadow, P.M., Campbell, B., Donovan, S.E., Amin, S., Gigliotti, B.J., Grabarek, Z., Hess, J.M., Stewart, C., Braunstein, L.Z., Arndt, P.F., Mordecai, S., Shih, A.R., Chaves, F., Zhan, T., Lubitz, C.C., Kim, J., Iafrate, A.J., Wirth, L., Parangi, S., Leshchiner, I., Daniels, G.H., Mootha, V.K., Dias-Santagata, D., Getz, G. & McFadden, D.G. 2018.

“Hürthle cell carcinoma of the thyroid (HCC) is a form of thyroid cancer recalcitrant to radioiodine therapy that exhibits an accumulation of mitochondria. We performed whole-exome sequencing on a cohort of primary, recurrent, and metastatic tumors, and identified recurrent mutations in DAXX, TP53, NRAS, NF1, CDKN1A, ARHGAP35, and the TERT promoter. Parallel analysis of mtDNA revealed recurrent homoplasmic mutations in subunits of complex I of the electron transport chain. Analysis of DNA copy-number alterations uncovered widespread loss of chromosomes culminating in near-haploid chromosomal content in a large fraction of HCC, which was maintained during metastatic spread. This work uncovers a distinct molecular origin of HCC compared with other thyroid malignancies.”

Staging and Diagnosis of Hürthle Cell Carcinoma

The extent, or stage of cancer, is used to determine the prognosis (i.e. the chance that a patient will recover, have a recurrence, or die of a disease) and the best treatment plan for an individual.

Spaulding, S.I., Ho, R., Everest, S. & Chai, R.L. 2020.

Background: Medullary thyroid carcinoma (MTC) is a somewhat rare, particularly aggressive form of thyroid cancer. The authors present what we believe to be the first case of MTC diagnosed solely on the basis of molecular testing, as well as a review of the literature concerning this topic and oncocytic variants of MTC.

Case description: A 30-year-old female patient with a 1.1 cm thyroid nodule underwent a fine-needle aspiration biopsy showing a Bethesda IV Hurthle cell neoplasm. Molecular testing of the specimen identified a RET M918 T mutation. The patient underwent a total thyroidectomy and bilateral central neck dissection. Initial pathologic analysis yielded a diagnosis of Hurthle cell adenoma. Based on the patient's known RET mutation, immunohistochemistry for calcitonin was performed and yielded a positive result. The final diagnosis was amended to an oncocytic variant of medullary thyroid carcinoma.

Discussion: Had this patient undergone fine-needle aspiration (FNA) biopsy without molecular testing or serum calcitonin measurement, the patient's disease would have been diagnosed as a Hurthle cell adenoma. Despite the lack of characteristic features of malignancy and the rarity of oncocytic MTC, the diagnostic pitfall in this oncocytic lesion was avoided due to molecular testing at the time of FNA biopsy.

Conclusion: This case draws attention to the unique clinical value of molecular testing in the diagnosis of MTC. The authors believe this case supports the consideration for molecular testing to prevent missed diagnoses in cases of rare benign-appearing disease.

Keywords: Fine-needle aspiration biopsy; Medullary thyroid carcinoma; Molecular testing; Oncocytic variant.

Li, O., Liu, P. & Zhang, H. 2017.

OBJECTIVE: This study aims to evaluate the diagnostic value of ultrasound in thyroid Hürthle cell tumors.

METHODS: A retrospective analysis was carried out on 27 patients with thyroid Hürthle cell tumors, in terms of the size, shape, boundary, echo, aspect ratio, cystic degeneration, calcification, peripheral halo sign and blood supply of the tumor, through surgical pathological validation. Then, these were compared with postoperative pathological results.

RESULTS: The maximum diameter of the thyroid Hürthle cell tumors is between 0.6 cm and 4.6 cm. It had an oval nodule with clear boundaries, an aspect ratio > 1 , and peripheral low-echo halos. Furthermore, 29.6% of tumors have even low-echo nodules without cystic changes, 48.1% and 22.1% have even medium or medium-low mixed echo nodules, and 44.4% have cystic changes in varying degrees. One nodule appeared with "micro-calcification", but pathological results confirmed that it was local collagen. Color Doppler blood flow imaging revealed that 88.8% of the nodules were surrounded with blood flow, filled with rich blood inside, and only 12.2% of the nodules had a little blood inside.

CONCLUSION: Thyroid Hürthle cell tumors have nodules with even or uneven echoes on the background of the normal echoes of the thyroid, with an aspect ratio of > 1 , clear boundaries and peripheral acoustic halos. Cystic changes, colloid crystallization and fibrosis can be seen inside in varying degrees. Ultrasonography has no significant value for the differential diagnosis of benign and malignant Hürthle cell tumors.

Li, W., Xia, S., Aronova, A., Min, I.M., Verma, A., Scognamiglio, T., Gray, K.D., Ullmann, T.M., Liang, H., Moore, M.D., Elemento, O., Zarnegar, R. & Fahey, T.J. 2018. CHL1 expression differentiates Hürthle cell carcinoma from benign Hürthle cell nodules. *J Surg Oncol.* 2018 Nov;118(6):1042-1049. doi: 10.1002/jso.25214. Epub 2018 Oct 12.

BACKGROUND AND OBJECTIVES: Hürthle cell carcinoma (HCC) is an unusual and relatively rare type of differentiated thyroid cancer. Currently, cytologic analysis of fine-needle aspiration biopsy is limited in distinguishing benign Hürthle cell neoplasms from malignant ones. The aim of this study was to determine whether differences in the expression of specific genes could differentiate HCC from benign Hürthle cell nodules by evaluating differential gene expression in Hürthle cell disease.

METHODS: Eighteen benign Hürthle cell nodules and seven HCC samples were analyzed by whole-transcriptome sequencing. Bioinformatics analysis was carried out to identify candidate differentially expressed genes. Expression of these candidate genes was re-examined by quantitative real-time polymerase chain reaction (qRT-PCR). Protein expression was quantified by immunohistochemistry.

RESULTS: Close homolog of L1 (CHL1) was identified as overexpressed in HCC. CHL1 was found to have greater than 15-fold higher expression in fragments per kilobase million in HCC compared with benign Hurthle cell tumors. This was confirmed by qRT-PCR. Moreover, the immunoreactivity score of the CHL1 protein was significantly higher in HCC compared with benign Hürthle cell nodules.

CONCLUSIONS: CHL1 expression may represent a novel and useful prognostic biomarker to distinguish HCC from benign Hürthle cell disease.

Researched and Authored by Prof Michael C Herbst

[D Litt et Phil (Health Studies); D N Ed; M Art et Scien; B A Cur; Dip Occupational Health; Dip Genetic Counselling; Dip Audiometry and Noise Measurement; Diagnostic Radiographer; Medical Ethicist]

Approved by Ms Elize Joubert, Chief Executive Officer [BA Social Work (cum laude); MA Social Work]

October 2020

Malith, V., Bombil, I., Harran, N. & Luvhengo, T.E. 2018.

BACKGROUND: Report of Hurthle cells following fine needle aspiration cytology from a thyroid nodule raises possibility of Hurthle cell carcinoma (HCC), which is a distinct entity and accounts for 3-10% of thyroid malignancies.

AIM: To determine if there are demographic and histopathological features which may be used to differentiate HCC from Hurthle cell adenoma (HCA).

METHOD: Histopathology records of patients who had thyroidectomy from January 2001 to October 2015 were reviewed. Data retrieved included indications for thyroidectomy, patients' demographics, histology and preoperative FNAC results.

RESULTS: At total of 2641 records were reviewed of which 25.6% (676/2641) were for neoplasms. 15.8% (107/676) of the neoplasms were Hurthle cell neoplasms (HCNs) and 25.2% (27/107) of HCNs were HCCs. 77.2% (71/92) of HCAs and 77.8% (21/27) of HCCs were from female patients. Preoperative FNAC results were available for 54.2% (58/107) and were suspicious of HCN in 12.1% (7/58). Average tumour size for HCCs and HCAs was 4.9 ± 2.7 cm and 3.5 ± 2.0 cm, respectively. The difference was statistically significant with a p-value of 0.016. The risk of malignancy increased from 11.1% in HCNs less than 1 cm to 53.8% for tumours which were greater than 4 cm in diameter.

CONCLUSION: HCNs are more common in females. The likelihood of HCC rises as the size of the HCN increases. Malignancy rate exceeds 50% for HCNs which are greater than 4 cm in diameter.

Treatment of Hürthle Cell Carcinoma

Treatment can be medical, surgical or radiation therapy or a combination of two or more regimen:

Surgical Treatment

Surgery is the main treatment for patients with Hürthle cell carcinoma. Surgical treatment is aimed at removal of the entire cancer, thereby minimising the risk of locally persistent or recurrent disease, providing adequate staging information, minimising risk without compromise to optimal cancer management, improving efforts for postoperative adjunctive treatment (e.g., radioactive iodide), and facilitating follow-up care.

Total thyroidectomy is usually recommended for patients with Hürthle cell carcinomas, whereas patients with Hürthle cell adenomas are generally treated with a thyroid lobectomy.

Although total thyroidectomy is generally considered the treatment of choice for Hürthle cell carcinoma, a lobectomy is usually performed first; if histologic sections show Hürthle cell carcinoma, as evidenced by vascular and/or capsular invasion, then a complete thyroidectomy is performed in a second surgery.

In clinically high-risk cases and in some institutions, a total thyroidectomy is performed as the first surgery based on frozen section results. Unfortunately, the majority of series have insufficient patient numbers to allow statistically valid conclusions regarding which of these approaches should become the standard.

Standard surgical wound care is usually appropriate. Patients should be monitored carefully for postoperative infection, hematoma, signs of recurrent laryngeal nerve injury (e.g., hoarseness), respiratory compromise, and signs of hypoparathyroidism and hypocalcemia.

Researched and Authored by Prof Michael C Herbst

[D Litt et Phil (Health Studies); D N Ed; M Art et Scien; B A Cur; Dip Occupational Health; Dip Genetic Counselling; Dip Audiometry and Noise Measurement; Diagnostic Radiographer; Medical Ethicist]

Approved by Ms Elize Joubert, Chief Executive Officer [BA Social Work (cum laude); MA Social Work]

October 2020

Medical Treatment

Surgical excision is the main treatment for patients with Hürthle cell carcinoma. Postoperative iodine-131 (¹³¹I) scanning is usually performed 4-6 weeks after surgery. No thyroid hormone treatment is administered to the patient in the interim. If uptake occurs in the thyroid bed or other sites, a treatment dose of ¹³¹I is administered, and another total body scan is obtained 4-7 days later.

- Radioactive iodine-131 treatment - This treatment is usually administered if postoperative iodine scanning shows uptake, in the thyroid bed or elsewhere.

¹³¹I therapy is used after surgery for three reasons. First, radioactive iodide destroys any remaining normal thyroid tissue, thereby enhancing the sensitivity of subsequent ¹³¹I total-body scanning and increasing the specificity of measurements of serum thyroglobulin for the detection of persistent or recurrent disease. Second, ¹³¹I therapy may destroy occult microscopic carcinoma. Third, the use of a large amount of ¹³¹I allows for total-body scanning, which is a more sensitive test for detecting persistent carcinoma.

Compared with other thyroid carcinomas, Hürthle cell cancer has a lower avidity for ¹³¹I; therefore, treatment with radioactive iodide has limited efficacy. Reportedly, approximately 10% of metastases take up radioiodine, compared with 75% of metastases from follicular carcinoma; thus, radioactive iodide treatment, which is the most useful nonsurgical therapy for recurrent well-differentiated thyroid carcinoma, is not always useful in patients with Hürthle cell carcinoma. This causes difficulty in the treatment of recurrences. Nevertheless, radioactive iodide treatment is used for most patients with Hürthle cell cancers after total and near-total thyroidectomy and in the treatment of patients with recurrent and metastatic Hürthle cell carcinoma.

There is limited evidence in the literature that redifferentiation therapy with retinoic acid may restore ¹³¹I uptake in some thyroid carcinomas that have lost their capability for radioiodine concentration; however, the benefits of this approach remain uncertain. Retinoic acid therapy also may be considered in patients with Hürthle cell carcinoma that does not take up radioactive iodide, although this is not yet a standard form of therapy.

- Levothyroxine treatment - The growth of thyroid tumour cells is controlled by thyroid-stimulating hormone (TSH), and the inhibition of TSH secretion with levothyroxine (T4) lowers recurrence rates and improves survival; therefore, T4 should be administered to all patients with thyroid carcinoma, regardless of the extent of thyroid surgery and other treatments.

Levothyroxine treatment is started after the treatment dose of ¹³¹I is administered. The effective dose of T4 in adults is 2.2-2.8 mcg/kg; children require higher doses. The adequacy of therapy is monitored by measuring serum TSH about 8-12 weeks after the treatment begins. The initial goal is a serum TSH concentration of 0.1 µU/mL or less and a serum triiodothyronine concentration within the reference range. When these guidelines are followed, T4 therapy does not have deleterious effects on the heart or bone.

Chemotherapy - Chemotherapy for metastatic differentiated thyroid cancer is usually ineffective. However, some experimental trials have yielded promising results.

Radiation Therapy

External radiotherapy - Hürthle cell carcinoma is considered a radiosensitive tumour. Radiation therapy may provide palliative relief from symptomatic metastases, control recurrent tumours, and prevent recurrence of advanced resected tumours.

External radiotherapy to the neck and mediastinum is indicated only in patients in whom surgical excision is incomplete or impossible. This therapy can also be considered for tumours that do not take up ¹³¹I.

Grani, G., Lamartina, L., Durante, C., Filetti, S. & Cooper, D.S. 2018.

“Follicular thyroid cancer is the second most common differentiated thyroid cancer histological type and has been overshadowed by its more common counterpart-papillary thyroid cancer-despite its unique biological behaviour and less favourable outcomes. In this Review, we comprehensively review the literature on follicular thyroid cancer to provide an evidence-based guide to the management of these tumours, to highlight the lack of evidence behind guideline recommendations, and to identify changes and challenges over the past decades in diagnosis, prognosis, and treatment. We highlight that correct identification of cancer in indeterminate cytological samples is challenging and ultrasonographic features can be misleading. Despite certain unique aspects of follicular thyroid cancer presentation and prognosis, no specific recommendations exist for follicular thyroid cancer and Hürthle cell carcinoma in evidence-based guidelines. Efforts should be made to stimulate additional research in this field.”

About Clinical Trials

Clinical trials are research studies that involve people. They are conducted under controlled conditions. Only about 10% of all drugs started in human clinical trials become an approved drug.

Clinical trials include:

- Trials to test effectiveness of new treatments
- Trials to test new ways of using current treatments
- Tests new interventions that may lower the risk of developing certain types of cancers
- Tests to find new ways of screening for cancer

The South African National Clinical Trials Register provides the public with updated information on clinical trials on human participants being conducted in South Africa. The Register provides information on the purpose of the clinical trial; who can participate, where the trial is located, and contact details.

For additional information, please visit: www.sanctr.gov.za/



Researched and Authored by Prof Michael C Herbst

[D Litt et Phil (Health Studies); D N Ed; M Art et Scien; B A Cur; Dip Occupational Health; Dip Genetic Counselling; Dip Audiometry and Noise Measurement; Diagnostic Radiographer; Medical Ethicist]

Approved by Ms Elize Joubert, Chief Executive Officer [BA Social Work (cum laude); MA Social Work]

October 2020

Sources and References Consulted or Utilised

EndocrineWeb

<http://www.endocrineweb.com/conditions/thyroid-cancer/hurthle-cell-thyroid-tumor>

Gopal, R.K., Kübler, K., Calvo, S.E., Polak, P., Livitz, D., Rosebrock, D., Sadow, P.M., Campbell, B., Donovan, S.E., Amin, S., Gigliotti, B.J., Grabarek, Z., Hess, J.M., Stewart, C., Braunstein, L.Z., Arndt, P.F., Mordecai, S., Shih, A.R., Chaves, F., Zhan, T., Lubitz, C.C., Kim, J., Iafrate, A.J., Wirth, L., Parangi, S., Leshchiner, I., Daniels, G.H., Mootha, V.K., Dias-Santagata, D., Getz, G. & McFadden, D.G. 2018. Widespread Chromosomal Losses and Mitochondrial DNA Alterations as Genetic Drivers in Hürthle Cell Carcinoma. *Cancer Cell*. 2018 Aug 13;34(2):242-255.e5. doi: 10.1016/j.ccell.2018.06.013.

Grani, G., Lamartina, L., Durante, C., Filetti, S. & Cooper, D.S. 2018. Follicular thyroid cancer and Hürthle cell carcinoma: challenges in diagnosis, treatment, and clinical management. *Lancet Diabetes Endocrinol*. 2018 Jun;6(6):500-514. doi: 10.1016/S2213-8587(17)30325-X. Epub 2017 Nov 5.

Karl Hürthle

https://en.wikipedia.org/wiki/Karl_H%C3%BCrthle

Li, O., Liu, P. & Zhang, H. 2017. Ultrasonic diagnosis for thyroid Hürthle cell tumor. *Cancer Biomark*. 2017 Sep 7;20(3):235-240. doi: 10.3233/CBM-160544.

Li, W., Xia, S., Aronova, A., Min, I.M., Verma, A., Scognamiglio, T., Gray, K.D., Ullmann, T.M., Liang, H., Moore, M.D., Elemento, O., Zarnegar, R. & Fahey, T.J. 2018. CHL1 expression differentiates Hürthle cell carcinoma from benign Hürthle cell nodules. *J Surg Oncol*. 2018 Nov;118(6):1042-1049. doi: 10.1002/jso.25214. Epub 2018 Oct 12.

Malith, V., Bombil, I., Harran, N. & Luvhengo, T.E. 2018. Demographic and histological subtypes of Hürthle cell tumours of the thyroid in a South African setting. *S Afr J Surg*. 2018 Sep;56(3):20-23.

Mayo Clinic

<http://www.mayoclinic.org/diseases-conditions/hurthle-cell-cancer/basics/causes/con-20025920>

<http://www.mayoclinic.org/diseases-conditions/hurthle-cell-cancer/basics/risk-factors/con-20025920>

<http://www.mayoclinic.org/diseases-conditions/hurthle-cell-cancer/basics/symptoms/con-20025920>

Medscape

<http://emedicine.medscape.com/article/279462-treatment#d10>

National Cancer Institute

<http://www.cancer.gov/about-cancer/treatment/clinical-trials/what-are-trials>

New Health Advisor

<http://www.newhealthadvisor.com/Hurthle-Cell-Carcinoma.html>

Spaulding, S.I., Ho, R., Everest, S. & Chai, R.L. 2020. The role of molecular testing in the diagnosis of medullary thyroid cancer: a case report of oncocytic medullary thyroid carcinoma and review of the literature. *Am J Otolaryngol*. Jan-Feb 2020;41(1):102312.

The American Association of Endocrine Surgeons

http://endocrinediseases.org/thyroid/cancer_prognosis.shtml

Thyroid

<http://www.newhealthadvisor.com/Hurthle-Cell-Carcinoma.html>

Xu, B. & Ghossein, R. 2018. Evolution of the histologic classification of thyroid neoplasms and its impact on clinical management. *Eur J Surg Oncol*. 2018 Mar;44(3):338-347. doi: 10.1016/j.ejso.2017.05.002. Epub 2017 May 18.

Younes, M.N., Yazici, Y.D., Kim, S., Jasser, S.A., El-Naggar, A.K. & Myers, J.N. 2006. Dual epidermal growth factor receptor and vascular endothelial growth factor receptor inhibition with NVP-AEE788 for the treatment of aggressive follicular thyroid cancer. *Clin Cancer Res*. 2006 Jun 1. 12(11 Pt 1):3425-34. [Medline]

Researched and Authored by Prof Michael C Herbst

[D Litt et Phil (Health Studies); D N Ed; M Art et Scien; B A Cur; Dip Occupational Health; Dip Genetic Counselling; Dip Audiometry and Noise Measurement; Diagnostic Radiographer; Medical Ethicist]

Approved by Ms Elize Joubert, Chief Executive Officer [BA Social Work (cum laude); MA Social Work]

October 2020