

Cancer Association of South Africa (CANSA)



Fact Sheet on Salivary Gland Cancer

Introduction

The salivary glands in mammals are exocrine glands, glands with ducts, that produce saliva. They also secrete amylase, an enzyme that breaks down starch into maltose. The gland is internally divided into lobules. Blood vessels and nerves enter the glands at the hilum and gradually branch out into the lobules.

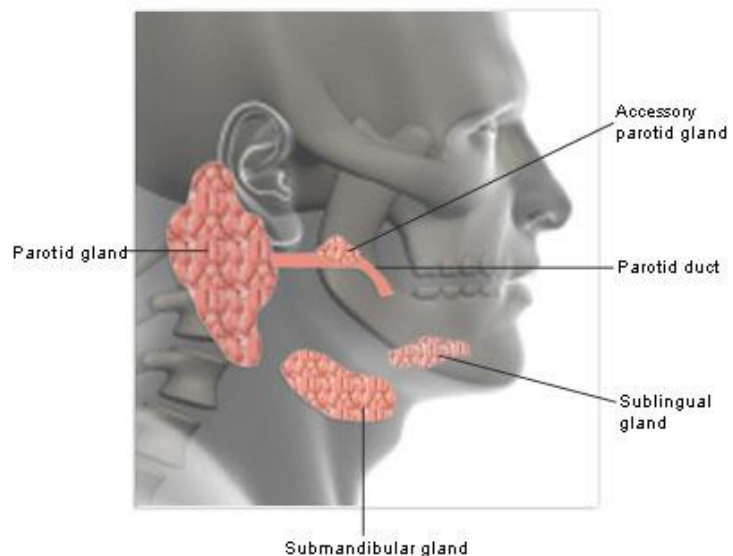
[Picture Credit: Salivary Glands]

The salivary glands consist of:

Parotid glands - the parotid gland is a salivary gland wrapped around the mandibular ramus in humans. It is one of a pair being the largest of the salivary glands, It secretes saliva through Stensen's ducts into the oral cavity, to facilitate mastication and swallowing and to begin the digestion of starches. The secretion produced is mainly serous in nature and enters the oral cavity via the Stensen's duct. It is located posterior to the mandibular ramus and in front of the mastoid process of temporal bone. This gland is clinically relevant in dissections of facial nerve branches while exposing the different lobes of it since any iatrogenic lesion will result in either loss of action or strength of muscles involved in facial expression.

Submandibular glands - the submandibular glands are a pair of glands located beneath the lower jaws, superior to the digastric muscles. The secretion produced is a mixture of both serous fluid and mucus and enters the oral cavity via Wharton's ducts. Approximately 70% of saliva in the oral cavity is produced by the submandibular glands, even though these are much smaller than the parotid glands. One can usually feel this gland, as it is in the upper neck and feels like a rounded ball. It is located about two fingers above the Adam's apple (on a man) and about two inches apart under the chin.

Sublingual glands - the sublingual glands are a pair of glands located beneath the tongue, anterior to the submandibular glands. The secretion produced is mainly mucus in nature, however it is



Researched and Authored by Prof Michael C Herbst

[D Litt et Phil (Health Studies); D N Ed; M Art et Scien; B A Cur; Dip Occupational Health; Dip Genetic Counselling; Dip Audiometry and Noise Measurement; Diagnostic Radiographer; Medical Ethicist]

Approved by Ms Elize Joubert, Chief Executive Officer [BA Social Work (cum laude); MA Social Work]

May 2020

Page 1

categorized as a mixed gland. Unlike the other two major glands, the ductal system of the sublingual glands do not have striated ducts and exit from 8-20 excretory ducts. Approximately 5% of saliva entering the oral cavity come from these glands.

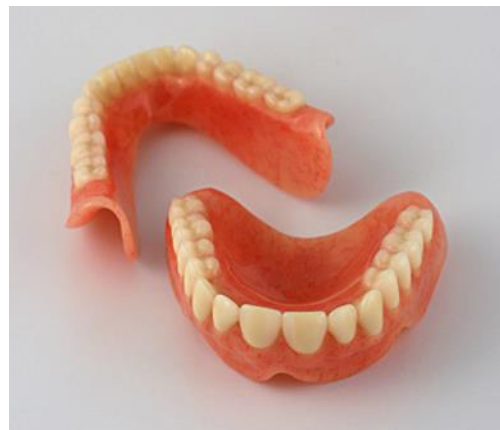Minor salivary glands - there are 800 - 1000 minor salivary glands located throughout the oral cavity within the submucosa of the oral mucosa in the tissue of the buccal, labial, as well as lingual mucosa, the soft palate, the lateral parts of the hard palate and the floor of the mouth. These are 1-2mm in diameter and unlike the other salivary glands, are not encapsulated by connective tissue, only surrounded by it. The gland is usually a number of acini connected in a tiny lobule. A minor salivary gland may have a common excretory duct with another gland, or may have its own excretory duct. The secretion of the gland is mainly mucous in nature (except for Von Ebner's glands) and have many functions such as coating the oral cavity with saliva. Problems with dentures are sometimes associated with minor salivary glands. The minor salivary glands are innervated by the seventh cranial or facial nerve.

Von Ebner's glands - Von Ebner's glands are glands found in circumvallate papillae of the tongue. It secretes a serous fluid that begin lipid hydrolysis and facilitates the perception of taste (Wikipedia).

Carlson, E.R. & Schlieve, T. 2019. Salivary Gland Malignancies. *Oral Maxillofac Surg Clin North Am.* 31 (1), 125-144. Feb 2019.

“Salivary gland tumors are rare pathologic entities that are derived from major and minor salivary gland tissue located throughout the head and neck region. These tumors are distinctly heterogenous, comprising numerous cell types, especially those deemed malignant. The incidence of malignant salivary gland tumors is widely distributed in both adult and pediatric patient populations. Accurate diagnosis and optimal treatment of these tumors pose challenges to both interpreting pathologists and ablative surgeons.”

[Picture Credit: Dentures]



Saliva and Dentures

Saliva is critical for retention of, and comfort in, wearing removable prostheses (dentures). In the denture wearing population, salivary wetting mechanics are necessary to create adhesion, cohesion and surface tension that ultimately lead to increased retention of prostheses. An intimate fit of denture function, provided that saliva is adequate in amount, flow and consistency. Saliva allows for the formation of a vacuum pressure on the seating of dentures and contributes significantly to denture retention and the wearer's satisfaction with the prosthesis.

Dentures can dislodge during function and the presence of adequate saliva and swallowing allows for repeated seating of the prosthesis and subsequent retention and denture stabilisation. Adhesion, cohesion and surface tension are interrelated, and they all depend on the presence of saliva.

Salivary Gland Cancer

Salivary gland cancer is a rare form of cancer that begins in the salivary glands. Salivary gland cancer can begin in any of the salivary glands in the mouth, neck or throat. It is uncontrolled division and growth of cells within the salivary glands.

- Signs of salivary gland cancer include a lump or trouble swallowing.
- Tests that examine the head, neck, and the inside of the mouth are used to detect (find) and diagnose salivary gland cancer.
- Certain factors affect treatment options and prognosis (chance of recovery).

Types of Salivary Gland Cancer

There are many different types of salivary gland tumours. They are classified according to the type of cells involved. By knowing the type of salivary gland tumour, doctors can determine the best treatment options.

The most common types of salivary gland tumours include:

- Basal cell adenoma
- Oncocytoma
- Warthin tumour
- Acinic cell carcinoma
- Adenocarcinoma
- Adenoid cystic carcinoma
- Clear cell carcinoma
- Malignant mixed tumour
- Mucoepidermoid carcinoma
- Oncocytic carcinoma
- Polymorphous low-grade adenocarcinoma
- Salivary duct carcinoma
- Squamous cell carcinoma

Incidence of Salivary Gland Cancer in South Africa

According to the outdated National Cancer Registry (2016), known for under reporting, the following number of salivary gland cancer cases was histologically diagnosed in South Africa during 2016:

Group - Males 2016	No of Cases Reported	Estimated Lifetime Risk	Percentage of All Cancers
All males	101	1:1 573	0,26%
Asian males	3	1:2 671	0,31%
Black males	41	1:2 700	0,32%
Coloured males	5	1:2 929	0,13%
White males	51	1:623	0,24%

Researched and Authored by Prof Michael C Herbst

[D Litt et Phil (Health Studies); D N Ed; M Art et Scien; B A Cur; Dip Occupational Health; Dip Genetic Counselling; Dip Audiometry and Noise Measurement; Diagnostic Radiographer; Medical Ethicist]

Approved by Ms Elize Joubert, Chief Executive Officer [BA Social Work (cum laude); MA Social Work]

May 2020

Group - Females 2016	No of Cases Reported	Estimated Lifetime Risk	Percentage of All Cancers
All females	81	1:2 986	0,19%
Asian females	2	1:2 000	0,16%
Black females	46	1:3 993	0,22%
Coloured females	12	1:1 863	0,26%
White females	21	1:2 041	0,12%

The frequency of histologically diagnosed cases of salivary gland cancer in South Africa for 2016 was as follows (National Cancer Registry, 2016):

Group - Males 2016	0 – 19 Years	20 – 29 Years	30 – 39 Years	40 – 49 Years	50 – 59 Years	60 – 69 Years	70 – 79 Years	80+ Years
All males	6	5	10	6	18	30	21	5
Asian males	0	1	0	0	1	1	0	0
Black males	5	2	8	3	5	11	6	0
Coloured males	0	2	1	1	0	1	1	0
White males	0	0	2	4	4	9	14	8

Group - Females 2016	0 – 19 Years	20 – 29 Years	30 – 39 Years	40 – 49 Years	50 – 59 Years	60 – 69 Years	70 – 79 Years	80+ Years
All females	6	5	9	15	13	18	13	7
Asian females	0	0	0	0	0	0	2	0
Black females	5	4	7	13	7	7	3	0
Coloured females	0	0	2	2	2	4	2	0
White females	1	1	0	0	4	7	6	2

N.B. In the event that the totals in any of the above tables do not tally, this may be the result of uncertainties as to the age, race or sex of the individual. The totals for 'all males' and 'all females', however, always reflect the correct totals.

According to **Bruni, et al.**, (2019), the burden of Cancer of the salivary glands for South Africa for 2018 is estimated as (based on Globocan estimates):

- Annual number of cancer of the salivary glands cases 166
- Annual number of cancer of the salivary glands deaths 95

Signs and Symptoms of Salivary Gland Cancer

Salivary gland cancer may not cause any symptoms. It is sometimes found during a regular dental check-up or physical examination. Symptoms caused by salivary gland cancer also may be caused by other conditions.

A doctor should be consulted if any of the following problems occur:

- a lump (usually painless) in the area of the ear, cheek, jaw, lip, or inside the mouth
- fluid draining from the ear
- trouble swallowing
- numbness in any part of the face
- muscle weakness on one side of the face
- pain in the face that does not go away

Researched and Authored by Prof Michael C Herbst

[D Litt et Phil (Health Studies); D N Ed; M Art et Scien; B A Cur; Dip Occupational Health; Dip Genetic Counselling; Dip Audiometry and Noise Measurement; Diagnostic Radiographer; Medical Ethicist]

Approved by Ms Elize Joubert, Chief Executive Officer [BA Social Work (cum laude); MA Social Work]

May 2020

- persistent pain in the area of a salivary gland
- trouble opening the mouth widely (Mayo Clinic; Medicine.Net).

Risk Factors

Anything that increases the chance of getting a disease is called a risk factor. Having a risk factor does not mean that you will get cancer; not having risk factors doesn't mean that you will not get cancer. Talk with your doctor if you think you may be at risk. Although the cause of most salivary gland cancers is not known, risk factors include the following:

- Older age.
- Treatment with radiation therapy to the head and neck.
- Being exposed to certain substances at work.

Diagnosis of Salivary Gland Cancer

The following procedures may be used in the diagnosis of salivary gland cancer:

Physical examination and history - an examination of the body to check general signs of health. The head, neck, mouth, and throat will be checked for signs of disease, such as lumps or anything else that seems unusual. A history of the patient's health habits and past illnesses and treatments will also be taken.

Magnetic resonance imaging (MRI) - a procedure that uses a magnet, radio waves, and a computer to make a series of detailed pictures of areas inside the body. This procedure is also called nuclear magnetic resonance imaging (NMRI).

Computerised Axial Tomography (CAT) scan - a procedure that makes a series of detailed pictures of areas inside the body, taken from different angles. The pictures are made by a computer linked to an x-ray machine. A dye may be injected into a vein or swallowed to help the organs or tissues show up more clearly.

Positron emission tomography scan (PET) - a procedure to find malignant tumour cells in the body. A small amount of radioactive glucose (sugar) is injected into a vein. The PET scanner rotates around the body and makes a picture of where glucose is being used in the body. Malignant tumour cells show up brighter in the picture because they are more active and take up more glucose than normal cells do.

Ultrasound examination - a procedure in which high-energy sound waves (ultrasound) are bounced off internal tissues or organs and make echoes. The echoes form a picture of body tissues called a sonogram. The picture can be printed to be looked at later.

Endoscopy - a procedure to look at organs and tissues inside the body to check for abnormal areas. For salivary gland cancer, an endoscope is inserted into the mouth to look at the mouth, throat, and larynx. An endoscope is a thin, tube-like instrument with a light and a lens for viewing.

Biopsy - the removal of cells or tissues so they can be viewed under a microscope by a pathologist to check for signs of cancer.

- Fine needle aspiration (FNA) biopsy : The removal of tissue or fluid using a thin needle. An FNA is the most common type of biopsy used for salivary gland cancer.
- incisional biopsy : The removal of part of a lump or a sample of tissue that doesn't look normal.

Researched and Authored by Prof Michael C Herbst

[D Litt et Phil (Health Studies); D N Ed; M Art et Scien; B A Cur; Dip Occupational Health; Dip Genetic Counselling; Dip Audiometry and Noise Measurement; Diagnostic Radiographer; Medical Ethicist]

Approved by Ms Elize Joubert, Chief Executive Officer [BA Social Work (cum laude); MA Social Work]

May 2020

- surgery : If cancer cannot be diagnosed from the sample of tissue removed during an FNA biopsy or an incisional biopsy, the mass may be removed and checked for signs of cancer.

Because salivary gland cancer can be hard to diagnose biopsy samples should be checked by a pathologist who has experience in diagnosing salivary gland cancer.

Pal, S., Mondal, S., Bose, K., Pradhan. R., Bandyapadhyay, A.& Bhattacharyya, D. 2019.

BACKGROUND: Minor salivary gland tumors (MSGTs) are less common than major salivary glands and involve only 15-20% of all salivary gland tumors. Most of the cases originate at intra- and peri-oral region. Minor salivary gland lesion cytology has been studied rarely in India.

AIMS: This present study was performed to evaluate the role of fine needle aspiration cytology (FNAC) in diagnosis of MSGTs and to explore the cases of cytohistological discrepancies in the study.

MATERIALS AND METHODS: This retrospective study was conducted over a 5-year period on 42 cases of MSGTs. In all the cases, cytology was correlated with histology and cytohistological discrepancies were searched. Sensitivity, specificity, and diagnostic efficacy were calculated using histopathology as gold standard.

RESULTS: We diagnosed 27 malignant (64.28%) and 15 benign (35.71%) MSGTs in cytological evaluation. We found two false negative and one false positive case in cytology. Sensitivity, specificity, and diagnostic accuracy of the study were 92.59%, 93.33%, and 92.85%, respectively.

CONCLUSION: FNAC is a minimally invasive and cost-effective procedure with high accuracy (92.85%) in the assessment of MSGTs and helps in the management of benign and malignant tumors.

Brown, A.L., Al-Samadi, A., Sperandio, M., Soares, A.B., Teixeira, L.N., Martinez, E.F., Demasi, A.P.D., de Araujo, V.C., Leivo, I., Salo, T. & Passador-Santos, F. 2019.

BACKGROUND: Adenoid cystic carcinoma (AdCC) and polymorphous adenocarcinoma (PAC) are included among the most common salivary gland cancers. They share clinical and histological characteristics, making their diagnosis challenging in specific cases. MicroRNAs (miRNA) are short, non-coding RNA sequences of 19 to 25 nucleotides in length that are involved in post-transcriptional protein expression. They have been shown to play important roles in neoplastic and non-neoplastic processes and have been suggested as diagnostic and prognostic markers.

METHODS: This study, using quantitative RT-PCR, investigated miR-150, miR-455-3p and miR-375 expression, in order to identify a possible molecular distinction between AdCC and PAC.

RESULTS: miRNA-150 and miRNA-375 expression was significantly decreased in AdCC and PAC compared with salivary gland tissue controls, whilst miRNA-455-3p showed significantly increased expression in AdCC when compared to PAC, ($p < 0.05$). miR-150, miR-357 and miR-455-3p expression in AdCC, PAC and control was not associated with age, gender nor with anatomic site (major and minor salivary glands) ($p > 0.05$).

CONCLUSION: MiR-455-3p could be used as a complimentary tool in the diagnosis of challenging AdCC cases. This article is protected by copyright. All rights reserved.

Seccia, V., Navari, E., Donadio, E., Boldrini, C., Ciregia, F., Ronci, M., Aceto, A., Dallan, I., Lucacchini, A., Casani, A.P., Mazzoni, M.R. & Giusti, L. 2019.

“The purpose of this study was to define the proteome profile of fine needle aspiration (FNA) samples of malignant major salivary gland tumors (MSGT) compared to benign counterparts, and to evaluate potential clinical correlations and future applications. Patients affected by MSGT ($n = 20$), pleomorphic adenoma (PA) ($n = 37$) and Warthin's tumor (WT) ($n = 14$) were enrolled. Demographic, clinical and histopathological data were registered for all patients. FNA samples were processed to obtain the protein extracts. Protein separation was obtained by two-dimensional electrophoresis (2-DE) and proteins were identified by mass spectrometry. Western blot analysis was performed to validate the

2-DE results. Statistical differences between groups were calculated by the Mann-Whitney U test for non-normal data. Spearman's rank correlation coefficient was calculated to evaluate correlations among suggested protein biomarkers and clinical parameters. Twelve and 27 differentially expressed spots were found for MSGT versus PA and MSGT versus WT, respectively. Among these, annexin-5, cofilin-1, peptidyl-prolyl-cis-trans-isomerase-A and F-actin-capping-alpha-1 were able to differentiate MSGT from PA, WT, and healthy samples. Moreover, STRING analysis suggested cofilin-1 as a key node of protein interactions. Some of the overexpressed proteins are related to some clinical factors of our cohort, such as survival and outcome. Our results suggest potential protein biomarkers of MSGT, which could allow for more appropriate treatment plans, as well as shedding light on the molecular pathways involved.”

Thierauf, J., Ramamurthy, N., Jo, V.Y., Robinson, H., Frazier, R.P., Gonzalez, J., Pacula, M., Dominguez Meneses, E., Nose, V., Nardi, V., Dias-Santagata, D., Le, L.P., Lin, D.T., Faquin, W.C., Wirth, L.J., Hess, J., lafrate, A.J. & Lennerz, J.K. 2019.

BACKGROUND: Adenoid cystic carcinoma (ACC) is an aggressive salivary gland malignancy without effective systemic therapies. Delineation of molecular profiles in ACC has led to an increased number of biomarker-stratified clinical trials; however, the clinical utility and U.S.-centric financial sustainability of integrated next-generation sequencing (NGS) in routine practice has, to our knowledge, not been assessed.

MATERIALS AND METHODS: In our practice, NGS genotyping was implemented at the discretion of the primary clinician. We combined NGS-based mutation and fusion detection, with MYB break-apart fluorescent in situ hybridization (FISH) and MYB immunohistochemistry. Utility was defined as the fraction of patients with tumors harboring alterations that are potentially amenable to targeted therapies. Financial sustainability was assessed using the fraction of global reimbursement.

RESULTS: Among 181 consecutive ACC cases (2011-2018), prospective genotyping was performed in 11% ($n = 20/181$; $n = 8$ nonresectable). Testing identified 5/20 (25%) NOTCH1 aberrations, 6/20 (30%) MYB-NFIB fusions (all confirmed by FISH), and 2/20 (10%) MYBL1-NFIB fusions. Overall, these three alterations (MYB/MYBL1/NOTCH1) made up 65% of patients, and this subset had a more aggressive course with significantly shorter progression-free survival. In 75% ($n = 6/8$) of nonresectable patients, we detected potentially actionable alterations. Financial analysis of the global charges, including NGS codes, indicated 63% reimbursement, which is in line with national (U.S.-based) and international levels of reimbursement **CONCLUSION:** Prospective routine clinical genotyping in ACC can identify clinically relevant subsets of patients and is approaching financial sustainability. Demonstrating clinical utility and financial sustainability in an orphan disease (ACC) requires a multiyear and multidimensional program.

IMPLICATIONS FOR PRACTICE: Delineation of molecular profiles in adenoid cystic carcinoma (ACC) has been accomplished in the research setting; however, the ability to identify relevant patient subsets in clinical practice has not been assessed. This work presents an approach to perform integrated molecular genotyping of patients with ACC with nonresectable, recurrent, or systemic disease. It was determined that 75% of nonresectable patients harbor potentially actionable alterations and that 63% of charges are reimbursed. This report outlines that orphan diseases such as ACC require a multiyear, multidimensional program to demonstrate utility in clinical practice.

Factors Affecting Treatment Options and Recovery

The treatment options and prognosis (chance of recovery) may depend on the following:

- The stage of the cancer (especially the size of the tumour).
- The type of salivary gland the cancer is in.

Researched and Authored by Prof Michael C Herbst

[D Litt et Phil (Health Studies); D N Ed; M Art et Scien; B A Cur; Dip Occupational Health; Dip Genetic Counselling; Dip Audiometry and Noise Measurement; Diagnostic Radiographer; Medical Ethicist]

Approved by Ms Elize Joubert, Chief Executive Officer [BA Social Work (cum laude); MA Social Work]

May 2020

- The type of cancer cells (how they look under a microscope).
- The patient's age and general health.

Risk Factors for Salivary Gland Cancer

The cause(s) of most salivary gland cancers are unknown, but the following factors may raise a person's risk of developing salivary gland cancer:

Age - two out of every three salivary gland cancers are found in people 55 and older, with an mean age of 64

Radiation exposure - radiation to the head or neck for another medical reason may increase the risk of salivary gland cancer

Radioactive substance exposure - in some reports, exposure to certain radioactive substances has been linked to an increased risk of salivary gland cancer

Environmental/occupational exposure - exposure to sawdust and chemicals used in the leather industry, pesticides, as well as some industrial solvents may increase the risk of some salivary gland cancer that occurs in the nose and sinuses

Other possible risk factors that researchers are investigating but have not proven include exposure to certain metals (nickel alloy dust) or minerals (silica dust), a diet low in vegetables and high in animal fats and exposure to hair dye or hairspray.

Treatment of Salivary Gland Cancer

Overview of treatment options:

- There are different types of treatment for patients with salivary gland cancer.
- Patients with salivary gland cancer should have their treatment planned by a team of doctors who are experts in treating head and neck cancer.
- Three types of standard treatment are used:
 - Surgery
 - Radiation therapy
 - Chemotherapy
- New types of treatment are being tested in clinical trials.
 - Radiosensitisers
- Patients may want to think about taking part in a clinical trial.
- Patients can enter clinical trials before, during, or after starting their cancer treatment.
- Follow-up tests may be needed.

Cancer of the salivary glands can often be cured, especially if found early. Although curing the cancer is the primary goal of treatment, preserving the function of the nearby nerves, organs and tissues is also very important.

Descriptions of the most common treatment options for salivary gland cancer may include:

Surgery - surgery is performed in nearly all cases of salivary gland cancer and is usually the first treatment. During surgery, a doctor performs an operation to remove the cancerous tumour and some of the healthy tissue around it (called a margin). A surgical oncologist is a doctor who specialises in treating cancer using surgery. The goal of surgery is to remove as much of the tumour as possible and leave negative margins (no trace of cancer in the healthy tissue).

Surgery is typically followed by additional treatment, most often radiation therapy. Sometimes, some people may need more than one operation to remove the cancer and to help restore the appearance and function of the tissues affected.

The type of surgery depends on the location and extent of the tumour:

- Parotidectomy - refers to the removal of the parotid gland. This surgery may involve the facial nerve. If cancer has spread to the facial nerve, frequently a nerve graft is necessary for the person to regain use of some facial muscles. Any tissue that is removed can often be restored by reconstructive surgery and tissue transplantation
- Endoscopic surgery - it is occasionally possible to remove the tumour by endoscopic surgery, which is less destructive to normal tissues than conventional surgery. This is used particularly when a salivary gland tumour begins in the paranasal area (around the nose) or in the larynx. However, this is rare. More often, a tumour may be found unexpectedly during endoscopic surgery for what is believed to be chronic sinusitis (inflammation)
- Neck dissection - a neck dissection is when the surgeon removes lymph nodes in the neck. This may be performed if the doctor suspects that the cancer has spread. A neck dissection may cause numbness of the ear, weakness when raising the arm above the head and weakness of the lower lip. These side effects are caused by injury to nerves in the area. Depending on the type of neck dissection, weakness of the lower lip and arm may go away in a few months. Weakness will be permanent if a nerve is removed as part of the dissection
- Reconstructive surgery - plastic, cosmetic and reconstructive surgery refers to a variety of operations performed in order to repair or restore body parts to look normal after removal of tissues and nerves to eliminate cancer

Surgery can have significant risks, because the cancer may be close to the eyes, mouth, brain, and important nerves and blood vessels in the area. Surgical side effects can include swelling of the face, mouth, and throat, making it difficult to breathe and swallow. Frequently, a person may receive a temporary tracheostomy (hole in the windpipe) to make breathing easier. Also, facial nerves may also be affected, either temporarily or permanently. Facial disfigurement may need to be addressed using reconstructive plastic surgery. If the maxilla (upper jaw) is removed, prosthodontists (a dentist who specialises in replacing teeth and parts of the jaw) play a large role in the rehabilitation process.

Occasionally, it is not possible to remove salivary gland cancer using surgery. This type of tumour is called inoperable. In these cases, doctors will recommend other treatment options.

Radiation therapy - is the use of high-energy x-rays or other particles to kill cancer cells. The most common type of radiation treatment is called external-beam radiation therapy, which is radiation given from a machine outside the body.

When radiation is given using implants, it is called internal radiation therapy or brachytherapy. Internal radiation therapy involves tiny pellets or rods containing radioactive materials that are surgically implanted in or near the cancer site. A radiation therapy regimen (schedule) usually consists of a specific number of treatments given over a set period of time.

A specific method of external radiation therapy, known as intensity modulated radiation therapy (IMRT), allows for more effective doses of radiation therapy to be delivered while reducing the damage to nearby healthy cells and causing fewer side effects.

For salivary gland tumours, it is most often used in combination with surgery, given either before or after the operation. It may also be given along with chemotherapy. Radiation therapy can also be the main treatment for certain types of tumours or if a person cannot have surgery or decides not to have surgery.

Proton therapy (also called proton beam therapy) may be used in instances when a tumour is located close to structures of the central nervous system (brain and spinal cord). It is a type of external-beam radiation therapy that uses protons rather than x-rays. At high energy, protons can destroy cancer cells.

Meyer, R., Wong, W.Y., Guzman, R., Burd, R. & Limesand, K. 2019.

“Hyposalivation and xerostomia create chronic oral complications that decrease the quality of life in head and neck cancer patients who are treated with radiotherapy. Experimental approaches to understanding mechanisms of salivary gland dysfunction and restoration have focused on in vivo models, which are handicapped by an inability to systematically screen therapeutic candidates and efficiencies in transfection capability to manipulate specific genes. The purpose of this salivary gland organotypic culture protocol is to evaluate maximal time of culture viability and characterize cellular changes following ex vivo radiation treatment. We utilized immunofluorescent staining and confocal microscopy to determine when specific cell populations and markers are present during a 30-day culture period. In addition, cellular markers previously reported in in vivo radiation models are evaluated in cultures that are irradiated ex vivo. Moving forward, this method is an attractive platform for rapid ex vivo assessment of murine and human salivary gland tissue responses to therapeutic agents that improve salivary function.”

Chemotherapy - is the use of drugs to kill cancer cells, usually by stopping the cancer cells' ability to grow and divide. Systemic chemotherapy is delivered through the bloodstream to reach cancer cells throughout the body. A chemotherapy regimen (schedule) usually consists of a specific number of cycles given over a set period of time. A patient may receive one drug at a time or a combination of different drugs at the same time.

Chemotherapy is seldom used in the initial treatment of salivary gland cancer. Combined treatments of chemotherapy with radiation therapy are being studied as part of clinical trials to research the combination's effectiveness. For salivary gland cancer, chemotherapy is most often used in later stage cancer or to treat symptoms to improve a patient's quality of life. Some chemotherapy drugs are available in clinical trials that may treat cancer at an earlier stage.

Researched and Authored by Prof Michael C Herbst

[D Litt et Phil (Health Studies); D N Ed; M Art et Scien; B A Cur; Dip Occupational Health; Dip Genetic Counselling; Dip Audiometry and Noise Measurement; Diagnostic Radiographer; Medical Ethicist]

Approved by Ms Elize Joubert, Chief Executive Officer [BA Social Work (cum laude); MA Social Work]

May 2020

Page 10

Fang, Q., Wu, J., Du W. & Zhang, X. 2019.

BACKGROUND: Distant metastasis (DM) is a common treatment failure pattern in acinic cell carcinoma (AciCC) of the major salivary glands; therefore, the main goal of this study was to analyse the predictors of DM in parotid AciCC.

METHODS: Consecutive patients with surgically treated parotid AciCC who were followed for at least 5 years were retrospectively reviewed. Data regarding age, sex, TNM stage, pathologic characteristics, surgical treatment, and follow-up examinations were collected and analysed. The primary end-point was DM control (DMC); the DMC survival was calculated from the date of surgery to the date of event or the latest follow-up examination and analysed by the Kaplan-Meier method. Independent prognostic factors were evaluated by the Cox proportional hazards method.

RESULTS: A total of 144 patients were included. Positive intraparotid nodes (IPNs) were noted in 34 (31.8%) patients. High-grade transformation was noted in 12 (8.3%) patients. A total of 83 (57.6%) patients underwent neck dissection, and neck node metastasis was proven in 37 (44.6%, 37/83) patients. The 10-year DMC rate was 86%. The Cox model analysis confirmed IPN metastasis (1.854 [1.061-4.144], $p = 0.011$) and high-grade transformation (4.219 [1.948-15.553], $p < 0.001$) as independent predictive factors of the DMC survival.

CONCLUSION: IPN metastasis and high-grade transformation are independent prognostic factors of the DMC survival.

About Clinical Trials

Clinical trials are research studies that involve people. They are conducted under controlled conditions. Only about 10% of all drugs started in human clinical trials become an approved drug.

Clinical trials include:

- Trials to test effectiveness of new treatments
- Trials to test new ways of using current treatments
- Tests new interventions that may lower the risk of developing certain types of cancers
- Tests to find new ways of screening for cancer

The **South African National Clinical Trials Register** provides the public with updated information on clinical trials on human participants being conducted in South Africa. The Register provides information on the purpose of the clinical trial; who can participate, where the trial is located, and contact details.

Medical Disclaimer

This Fact Sheet is intended to provide general information only and, as such, should not be considered as a substitute for advice, medically or otherwise, covering any specific situation. Users should seek appropriate advice before taking or refraining from taking any action in reliance on any information contained in this Fact Sheet. So far as permissible by law, the Cancer Association of South Africa (CANSA) does not accept any liability to any person (or his/her dependants/estate/heirs) relating to the use of any information contained in this Fact Sheet.

Whilst the Cancer Association of South Africa (CANSA) has taken every precaution in compiling this Fact Sheet, neither it, nor any contributor(s) to this Fact Sheet can be held responsible for any action

Researched and Authored by Prof Michael C Herbst

[D Litt et Phil (Health Studies); D N Ed; M Art et Scien; B A Cur; Dip Occupational Health; Dip Genetic Counselling; Dip Audiometry and Noise Measurement; Diagnostic Radiographer; Medical Ethicist]

Approved by Ms Elize Joubert, Chief Executive Officer [BA Social Work (cum laude); MA Social Work]

May 2020

(or the lack thereof) taken by any person or organisation wherever they shall be based, as a result, direct or otherwise, of information contained in, or accessed through, this Fact Sheet.



Sources and References Consulted or Utilised

American Cancer Society

<http://www.cancer.org/cancer/salivaryglandcancer/detailedguide/salivary-gland-cancer-diagnosis>

Brown, A.L., Al-Samadi, A., Sperandio, M., Soares, A.B., Teixeira, L.N., Martinez, E.F., Demasi, A.P.D., de Araujo, V.C., Leivo, I., Salo, T. & Passador-Santos, F. 2019. MiR-455-3p, miR-150 and miR-375 are aberrantly expressed in salivary gland adenoid cystic carcinoma and polymorphous adenocarcinoma. *J Oral Pathol Med.* 2019 Jun 5. doi: 10.1111/jop.12894. [Epub ahead of print]

Bruni, L., Albero, G., Serrano, B., Mena, M., Gómez, D., Muñoz, J., Bosch, F.X. & de Sanjosé, S. 2019. ICO/IARC Information Centre on HPV and Cancer (*HPV Information Centre*). Human Papillomavirus and Related Diseases in South Africa. Summary Report 17 June 2019. [Date Accessed]

Cancer.Net

<http://www.cancer.net/cancer-types/salivary-gland-cancer/treatment-options>

<http://www.cancer.net/cancer-types/salivary-gland-cancer/risk-factors>

Carlson, E.R. & Schlieve, T. 2019. Salivary Gland Malignancies. *Oral Maxillofac Surg Clin North Am.* 31 (1), 125-144. Feb 2019.

Dentures

https://www.google.co.za/search?q=dentures&source=lnms&tbn=isch&sa=X&ei=HGT2UdPOGILB0gXlqYGoBg&sqi=2&ved=0CAcQ_AUoAQ&biw=1366&bih=614#facrc=_&imgdii=_&imgrc=Ohmv3Aa_TjPcSM%3A%3BY8ZXcmb7I79wiM%3Bhttp%253A%252F%252F1.bp.blogspot.com%252F_InQfzTT_mU0%252FS97fAZOLKwI%252FAAAAAAABE%252FDH4jp8nq0tM%252Fs1600%252Facylic_dentures_1%25255B1%25255D.jpg%3Bhttp%253A%252F%252Fpearlbited.blogspot.com%252F%3B500%3B434

Fang, Q., Wu, J., Du W. & Zhang, X. 2019. Predictors of distant metastasis in parotid acinic cell carcinoma. *BMC Cancer.* 2019 May 21;19(1):475. doi: 10.1186/s12885-019-5711-4.

Guident

<http://www.guident.net/prostodontics/saliva-and-denture-retention-a-review.html>

Mayo Clinic

<http://www.mayoclinic.com/health/salivary-gland-cancer/DS00708>

Medicine.Net

http://www.medicinenet.com/salivary_gland_cancer/page2.htm#what_are_symptoms_and_signs_of_salivary_gland_cancer

Meyer, R., Wong, W.Y., Guzman, R., Burd, R. & Limesand, K. 2019. Radiation treatment of organotypic cultures from submandibular and parotid salivary glands: models kry in vivo characteristics. *J Vis Exp.* 2019 May 17;(147). doi: 10.3791/59484.

National Cancer Institute

<http://www.cancer.gov/about-cancer/treatment/clinical-trials/what-are-trials>

<https://www.cancer.gov/types/head-and-neck/patient/salivary-gland-treatment-pdq>

Researched and Authored by Prof Michael C Herbst

[D Litt et Phil (Health Studies); D N Ed; M Art et Scien; B A Cur; Dip Occupational Health; Dip Genetic Counselling; Dip Audiometry and Noise Measurement; Diagnostic Radiographer; Medical Ethicist]

Approved by Ms Elize Joubert, Chief Executive Officer [BA Social Work (cum laude); MA Social Work]

May 2020

Pal, S., Mondal, S., Bose, K., Pradhan, R., Bandyapadhyay, A. & Bhattacharyya, D. 2019. Fine needle aspiration cytology of minor salivary gland tumors: a retrospective 5-year study of 42 cases in a tertiary care hospital. *J Cancer Res Ther.* 2019 Jul-Sep;15(3):686-689. doi: 10.4103/0973-1482.191055.

Salivary Glands

https://www.google.co.za/search?q=salivary+glands&source=lnms&tbn=isch&sa=X&ei=2V72UYuoFYa0hAf0vYDYDA&sqi=2&ved=0CAcQ_AUoAQ&biw=1366&bih=614#facrc=_&imgdii=_&imgsrc=sSBCPzf2cfW0HM%3A%3BWtj6n62XMJs8SM%3Bhtp%253A%252F%252Fwww.zadehmd.com%252Fimages%252F9654.jpg%3Bhttp%253A%252F%252Fwww.zadehmd.com%252Fparotid-salivary-gland-surgery.php%3B400%3B320

Salivary Gland Cancer

<https://www.mayoclinic.org/diseases-conditions/salivary-gland-cancer/symptoms-causes/syc-20354151>

Seccia, V., Navari, E., Donadio, E., Boldrini, C., Ciregia, F., Ronci, M., Aceto, A., Dallan, I., Lucacchini, A., Casani, A.P., Mazzoni, M.R. & Giusti, L. 2019. *Head Neck Pathol.* 2019 May 16. doi: 10.1007/s12105-019-01040-2. [Epub ahead of print]

Stages of Salivary Gland Cancer

<https://www.cancer.gov/types/head-and-neck/patient/salivary-gland-treatment-pdq>

Thierauf, J., Ramamurthy, N., Jo, V.Y., Robinson, H., Frazier, R.P., Gonzalez, J., Pacula, M., Dominguez Meneses, E., Nose, V., Nardi, V., Dias-Santagata, D., Le, L.P., Lin, D.T., Faquin, W.C., Wirth, L.J., Hess, J., Iafrate, A.J. & Lennerz, J.K. 2019. Clinically integrated molecular diagnostics in adenoid cystic carcinoma. *Oncologist.* 2019 Mar 29. pii: theoncologist.2018-0515. doi: 10.1634/theoncologist.2018-0515. [Epub ahead of print]

TNM Classification Help

<http://cancerstaging.blogspot.com/2005/02/salivary-glands.html>

Wikipedia

http://en.wikipedia.org/wiki/Salivary_gland