

Cancer Association of South Africa (CANSA)

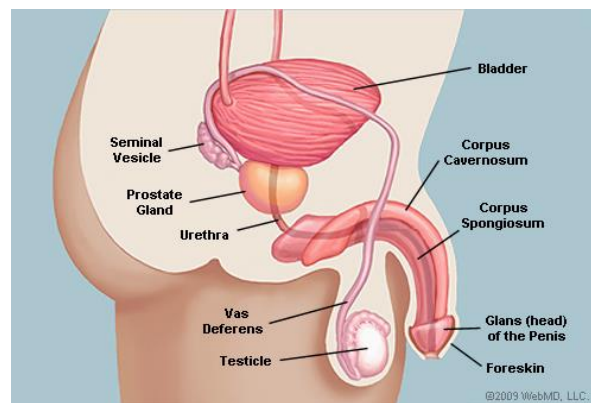


Fact Sheet on Penile Intraepithelial Neoplasia (PeIN)

Introduction

The penis is the male sex organ, reaching its full size during puberty. In addition to its sexual function, the penis acts as a conduit for urine to leave the body.

[Picture Credit: Male Reproductive System]



The penis is made of several parts:

- Glans (head) of the penis: In uncircumcised men, the glans is covered with pink, moist tissue called mucosa. Covering the glans is the foreskin (prepuce). In circumcised men, the foreskin is surgically removed and the mucosa on the glans transforms into dry skin.
- Corpus cavernosum: Two columns of tissue running along the sides of the penis. Blood fills this tissue to cause an erection.
- Corpus spongiosum: A column of sponge-like tissue running along the front of the penis and ending at the glans penis; it fills with blood during an erection, keeping the urethra -- which runs through it -- open.
- The urethra runs through the corpus spongiosum, conducting urine out of the body.

An erection results from changes in blood flow in the penis. When a man becomes sexually aroused, nerves cause blood vessels in the penis to expand. More blood flows in and less flows out of the penis, hardening the tissue in the corpus cavernosum.

Intraepithelial Neoplasia (IN)

Intraepithelial neoplasia (IN) is an *in situ* carcinoma confined to an epithelium that may superficially penetrate adnexal (associated) glands, measuring < either 3mm or 5mm depending on the criteria used. IN is adjectivally modified according to the site of origin.

The following Intraepithelial neoplasia have been identified:

- AIN Anal intraepithelial neoplasia

Researched and Authored by Prof Michael C Herbst

[D Litt et Phil (Health Studies); D N Ed; M Art et Scien; B A Cur; Dip Occupational Health; Dip Genetic Counselling; Diagnostic Radiographer; Dip Audiometry and Noise Measurement; Medical Ethicist]

Approved by Ms Elize Joubert, Chief Executive Officer [BA Social Work (cum laude); MA Social Work]

January 2020

- CIN Cervical intraepithelial neoplasia
- DIN Ductal intraepithelial neoplasia
- OIN Oral intraepithelial neoplasia
- PAIN Perianal intraepithelial neoplasia
- PeNI Penile intraepithelial neoplasia
- PIN Prostatic (or rarely Penile) intraepithelial neoplasia
- VAIN Vaginal intraepithelial neoplasia
- VIN Vulvar intraepithelial neoplasia

Hoekstra, R.J., Trip, E.J. Ten Kate, F.J., Horenblas, S. & Lock, M.T. 2018.

OBJECTIVE: To determine the incidence of penile intraepithelial neoplasia in the Netherlands using a nationwide histopathology registry and to discuss the nomenclature of premalignant penile lesions.

METHODS: Data from patients in the Netherlands diagnosed with a premalignant penile lesion between January 1998 and December 2007 were collected from the nationwide histopathology registry (PALGA); this database covers all pathology reports of inhabitants in the Netherlands. The premalignant lesions included were erythroplasia of Queyrat; Bowen's disease; bowenoid papulosis; mild, moderate and severe dysplasia; and carcinoma in situ of the penis. The terminology used in the pathological reports was translated to penile intraepithelial neoplasia. The grading was made analogous to that of vulvar premalignant lesions.

RESULTS: The PALGA database enrolled 380 patients with premalignant penile lesions. Severe premalignant lesions, penile intraepithelial neoplasia III, were found in 254 patients (67%), penile intraepithelial neoplasia II in 84 (22%) and penile intraepithelial neoplasia I in 42 patients (11%). Most lesions were located on the prepuce (45%), followed by glans (38%) and shaft (3%). The median age of patients with penile intraepithelial neoplasia was 58 years. Progression to malignant disease occurred (2% for penile intraepithelial neoplasia I vs 7% for penile intraepithelial neoplasia III) in 26 patients.

CONCLUSIONS: Penile intraepithelial neoplasia is a rarely diagnosed condition. Because of the wide variation of terms used for premalignant intraepithelial neoplasia of the penis, we recommend restricting this nomenclature to penile intraepithelial neoplasia.

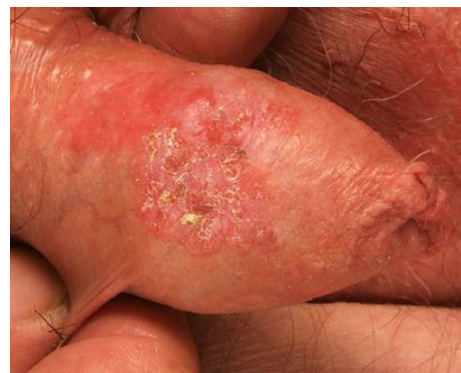Penile Intraepithelial Neoplasia (PeIN)

Penile intraepithelial neoplasia is a rare pre-cancerous disease of the outer skin layer (epidermis) of the penis.

[Picture Credit: Penile Intraepithelial Neoplasia 1]

Other names for penile intraepithelial neoplasia include:

- Erythroplasia of Queyrat
- Bowen disease of the penis
- in-situ squamous cell carcinoma of the penis
- P.I.N.



Incidence of Penile Cancer in South Africa

According to the outdated National Cancer Registry (2014), known for under reporting of cancer incidence, the following number of penile cancer cases was histologically diagnosed in South Africa during 2014. Histologically diagnosed means that a small piece of tissue (biopsy) was obtained and forwarded to a recognised laboratory where a qualified pathologist confirmed the diagnosis of cancer under a microscope:

Group 2014	Actual Number of Cases	Estimated Lifetime Risk	Percentage of All Cancers
All Males	172	1:1 243	0,47%
Asian males	4	1:1 864	0,43%
Black males	138	1:1 106	1,24%
Coloured males	11	1:1 692	0,26%
White males	19	1:1 775	0,09%

The frequency of histologically diagnosed cases of penile cancer in South Africa for 2014 was as follows (National Cancer Registry, 2014):

Group 2014	0 – 19 Years	20 – 29 Years	30 – 39 Years	40 – 49 Years	50 – 59 Years	60 – 69 Years	70 – 79 Years	80+ Years
All males	0	6	27	60	28	24	13	4
Asian males	0	0	2	1	0	1	0	0
Black males	0	5	21	56	26	16	4	3
Coloured males	0	1	1	2	1	4	2	0
White males	0	0	3	4	1	3	7	1

According to **Globocan** (2019), and **Bruni et al.** (2019), the incidence of Penile Cancer (estimate for 2018) was 244 cases (all males).

Olesen, T.B., Sand, F.L., Rasmussen, C.L., Albieri, V., Toft, B.G., Norrild, B., Mun, K, C & Kliær S.K. 2018.

BACKGROUND: Although previous meta-analyses have examined human papillomavirus (HPV) DNA prevalence in penile cancer, none, to our knowledge, have assessed pooled HPV DNA prevalence in penile intraepithelial neoplasia or p16^{INK4a} percent positivity in penile cancer and penile intraepithelial neoplasia. Therefore, we aimed to examine the prevalence of HPV DNA and p16^{INK4a} positivity in penile cancer and penile intraepithelial neoplasia worldwide.

METHODS: In this systematic review and meta-analysis, we searched PubMed, Embase, and the Cochrane Library until July 24, 2017, for English-language articles published from Jan 1, 1986, onwards reporting the prevalence of HPV DNA and p16^{INK4a} positivity, either alone or in combination, in at least five cases of penile cancer or penile intraepithelial neoplasia. Only studies that used PCR or hybrid capture for the detection of HPV DNA and immunohistochemical staining or methylation for the detection of p16^{INK4a} were included. Data were extracted and subsequently crosschecked, and inconsistencies were discussed to reach consensus. Using random-effects models, we estimated the pooled prevalence and 95% CI of HPV DNA and p16^{INK4a} positivity in penile cancer and penile intraepithelial neoplasia, stratifying by histological subtype and HPV DNA or p16^{INK4a} detection method. Type-specific prevalence of HPV6, HPV11, HPV16, HPV18, HPV31, HPV33, and HPV45 in penile cancer was estimated.

Researched and Authored by Prof Michael C Herbst

[D Litt et Phil (Health Studies); D N Ed; M Art et Scien; B A Cur; Dip Occupational Health; Dip Genetic Counselling; Diagnostic Radiographer; Dip Audiometry and Noise Measurement; Medical Ethicist]

Approved by Ms Elize Joubert, Chief Executive Officer [BA Social Work (cum laude); MA Social Work]

January 2020

FINDINGS: Our searches identified 1836 non-duplicate records, of which 73 relevant papers (71 studies) were found to be eligible. The pooled HPV DNA prevalence in penile cancer (52 studies; n=4199) was 50.8% (95% CI 44.8-56.7; $I^2=92.6\%$, $p_{\text{heterogeneity}}<0.0001$). A high pooled HPV DNA prevalence was seen in basaloid squamous cell carcinomas (84.0%, 95% CI 71.0-93.6; $I^2=48.0\%$, $p_{\text{heterogeneity}}=0.0197$) and in warty-basaloid carcinoma (75.7%, 70.1-81.0; $I^2=0\%$, $p_{\text{heterogeneity}}=0.52$). The predominant oncogenic HPV type in penile cancer was HPV16 (68.3%, 95% CI 58.9-77.1), followed by HPV6 (8.1%, 4.0-13.7) and HPV18 (6.9%, 2.9-12.4). The pooled HPV DNA prevalence in penile intraepithelial neoplasia (19 studies; n=445) was 79.8% (95% CI 69.3-88.6; $I^2=83.2\%$, $p_{\text{heterogeneity}}<0.0001$). The pooled p16^{INK4a} percent positivity in penile cancer (24 studies; n=2295) was 41.6% (95% CI 36.2-47.0; $I^2=80.6\%$, $p_{\text{heterogeneity}}<0.0001$), with a high pooled p16^{INK4a} percent positivity in HPV-related squamous cell carcinoma (85.8%, 95% CI 72.1-95.4; $I^2=56.4\%$, $p_{\text{heterogeneity}}=0.0011$) as compared with non-HPV-related squamous cell carcinoma (17.1%, 7.9-29.1; $I^2=78.3\%$, $p_{\text{heterogeneity}}<0.0001$). Moreover, among HPV-positive cases of penile cancer, the p16^{INK4a} percent positivity was 79.6% (95% CI 65.7-90.7; $I^2=89.9\%$, $p_{\text{heterogeneity}}<0.0001$), compared with 18.5% (9.6-29.6; $I^2=89.3\%$, $p_{\text{heterogeneity}}<0.0001$) in HPV-negative penile cancers. The pooled p16^{INK4a} percent positivity in penile intraepithelial neoplasia (six studies; n=167) was 49.5% (95% CI 18.6-80.7).

INTERPRETATION: A large proportion of penile cancers and penile intraepithelial neoplasias are associated with infection with HPV DNA (predominantly HPV16), emphasising the possible benefits of HPV vaccination in men and boys.

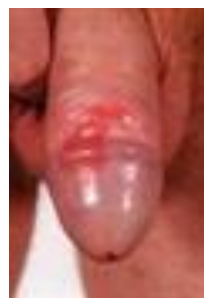Kristiansen, S., Svensson, Å., Drevin, L., Forslund, O., Torbrand, C. & Biartling, C. 2018.

“Studies on risk factors for penile intraepithelial neoplasia have been small in size, have not distinguished penile intraepithelial neoplasia from invasive cancer, and have relied on self-reported information. This study investigated risk factors for penile intraepithelial neoplasia in a cohort of 580 penile intraepithelial neoplasia cases and 3,436 controls using information from 7 Swedish registers. Cases with penile intraepithelial neoplasia had increased odds ratios (ORs) for inflammatory skin diseases (14.7, 95% CI 6.5-33.4) including lichen ruber (12.0, 95% CI 3.0-48.0), indicating lichen ruber to be an important risk factor. Increased ORs were also observed for diseases of the prepuce (4.0, 95% CI 2.2-7.4), immunosuppressive drugs (5.0, 95% CI 2.5-9.8), penile surgical procedures (4.8, 95% CI 2.2-10.8), balanitis (9.2, 95% CI 5.0-16.8), genital warts (9.9, 95% CI 4.3-22.7) and organ transplantation (7.0, 95% CI 2.4-20.8). This study demonstrates important risk factors for penile intraepithelial neoplasia, providing knowledge that can help prevent the development of penile cancer.”

Clinical Features of Penile Intraepithelial Neoplasia (PeIN)

The clinical features of PeIN include:

- Whitish areas in glans penis, coronal sulcus or inner foreskin
- Erythema (redness) and ulceration may predominate in some cases
- It may be found as an exclusive *in situ* lesion or associated with an invasive component
- It may be difficult to distinguish from squamous hyperplasia



[Picture Credit: Penile Intraepithelial Neoplasia 2]

Researched and Authored by Prof Michael C Herbst

[D Litt et Phil (Health Studies); D N Ed; M Art et Scien; B A Cur; Dip Occupational Health; Dip Genetic Counselling; Diagnostic Radiographer; Dip Audiometry and Noise Measurement; Medical Ethicist]

Approved by Ms Elize Joubert, Chief Executive Officer [BA Social Work (cum laude); MA Social Work]

January 2020

Page 4

Histologic Classification of Penile Intraepithelial Neoplasia (PeIN)

Penile squamous cell carcinomas (SCCs) and their corresponding precancerous lesions can be classified in 2 major groups:

- human papillomavirus (HPV) related
- human papillomavirus (HPV) unrelated

In the former (warty and basaloid SCC), there is a predominance of undifferentiated basaloid cells. In the latter (e.g., usual, papillary, and verrucous SCC), the predominant cell is larger with abundant eosinophilic cytoplasm.

Diagnosis of Penile Intraepithelial Neoplasia (PeIN)

The diagnosis is often delayed, because penile intraepithelial neoplasia may resemble other conditions such as balanitis, candidiasis, dermatitis and psoriasis..

Lesions are single or multiple, red plaques on the glans or inner aspect of the foreskin. They may have a smooth, velvety, moist, scaly, eroded or warty surface. The following signs and symptoms may occur:

- Redness and inflammation
- Itching
- Crusting or scaling
- Pain
- Ulcers
- Bleeding
- In the late stages, discharge from penis, difficulty pulling back foreskin or difficulty passing urine

Chan, S.L., Watchorn, R.E., Panagou, E., Panou, E., Ong, E.L., Heelan, K., Haider, A., Freeman, A. & Bunker, C.B. 2018.

BACKGROUND/OBJECTIVES: The clinical diagnosis of penile intraepithelial neoplasia is challenging. No specific dermoscopic criteria for penile intraepithelial neoplasia have been described in the literature. This study aimed to describe and evaluate the dermoscopic features of penile intraepithelial neoplasia.

METHODS: Clinical and dermoscopic images of 11 patients with histopathologically confirmed penile intraepithelial neoplasia were recorded and evaluated.

RESULTS: The most frequent dermoscopic features were the presence of structureless areas (100%, structureless pink 72.7%) and vascular structures (81.8%), particularly dotted vessels (72.7%). Other findings included the absence of a pigment network (100%); scale (45.5%); scar-like areas (45.5%); erosions (27.3%); and pigmentation consisting of brown-grey dots and globules (27.3%).

CONCLUSIONS: The dermoscopic features that characterise penile intraepithelial neoplasia are structureless pink areas and a prominent vascular pattern (mainly clustered dotted vessels). Dermoscopy is a useful tool that can aid in the diagnosis and surveillance of penileintraepithelial neoplasia.

Treatment of Penile Intraepithelial Neoplasia (PeIN)

Sin biopsy should be performed to confirm the diagnosis, as it may resemble other forms of chronic balanitis. Biopsy is also essential to rule out invasive squamous cell carcinoma, which requires more aggressive treatment.

Mohs micrographic surgery appears to be highly effective and the surgical treatment of choice in severe or recurrent cases of penile intraepithelial neoplasia.

The disease recurs in 3-10% of patients, so close follow-up is necessary to ensure a complete cure.

Partners of patients with penile intraepithelial neoplasia should be screened for other forms of intraepithelial neoplasia caused by human papilloma virus (HPV) in the genital area (cervical, vulvar and anal cancer).

Many national immunisation programmes now include a vaccine against the causative human papillomaviruses HPV-16 and 18. Vaccination of boys and young men should be considered for inclusion, to reduce the risk of developing penile intraepithelial cancer in the future.

Circumcision - circumcision is the removal of the foreskin. If the cancer only affects the foreskin, this may be the only treatment that will be needed. Circumcision is also done if the patient needs radiotherapy treatment.

A person can have a circumcision under a local or a general anaesthetic. After the operation the penis will be slightly swollen and bruised for about a week. There will be some stitches that will dissolve after a week to 10 days. It is important to keep the wound clean and one should wash or clean it as directed. The patient may have some pain for a few days, and need to take a mild painkiller such as paracetamol.

Some men worry about their sex lives after being circumcised. However there is no evidence that men who are circumcised are less sensitive or have any more difficulty getting an erection after the surgery.

Mohs micrographic surgery (MMS) - this is a specialist type of surgery and one may have to be referred to another hospital to have it. Mohs micrographic surgery (MMS) is sometimes used for verrucous carcinoma, a rare type of squamous cell penile cancer.

MMS is a slow process because a small amount of cancer tissue is removed at a time. But the person will keep as much healthy skin as possible. During surgery the tissue is immediately examined under a microscope. If the tissue contains cancer cells, more tissue is removed and examined. The surgeon continues in this way until they have removed all the cancer. This treatment is not suitable for everyone.

Nadimi, E.E. & Hendi, A. 2018.

“Penile squamous cell carcinoma (SCC) with considerable urethral extension is uncommon and difficult to manage. It often is resistant to less invasive and nonsurgical treatments and frequently

Researched and Authored by Prof Michael C Herbst

[D Litt et Phil (Health Studies); D N Ed; M Art et Scien; B A Cur; Dip Occupational Health; Dip Genetic Counselling; Diagnostic Radiographer; Dip Audiometry and Noise Measurement; Medical Ethicist]

Approved by Ms Elize Joubert, Chief Executive Officer [BA Social Work (cum laude); MA Social Work]

January 2020

results in partial or total penectomy, which can lead to cosmetic disfigurement, functional issues, and psychological distress. We report a case of penile SCC in situ with considerable urethral extension with a focus of cells suspicious for moderately well-differentiated and invasive SCC that was treated with Mohs micrographic surgery (MMS). A review of the literature on penile tumors treated with MMS also is provided.”

Laser surgery and cryotherapy - doctors use these treatments for carcinoma *in situ* (CIS))

- Laser surgery - this is the most common. The surgeon uses a powerful beam of light that acts like a knife. It cuts away the tumour but does not go too deep into the tissue. If having laser treatment the patient will have a general anaesthetic.
- Cryotherapy - cryotherapy uses liquid nitrogen to freeze and kill the cancer cells. The doctor places a probe on the area to freeze the cells. After having had cryotherapy the skin usually develops a blister, which may form a scab or crust. The blister and scab usually fall off after a couple of weeks. Once the skin has healed it may be a different colour, usually leaving a paler scar.

Some individuals can have cryotherapy under a local anaesthetic. But it can take over an hour, so the doctor might give him either a sedative or a general anaesthetic.

Wide local excision - this is when the cancer is removed along with a border of healthy tissue around it. This is called a clear margin of tissue. The doctor removes this border of healthy tissue to lower the risk of the cancer coming back. The surgeon will send the tissue sample to the laboratory, where a pathologist will look at the cells under a microscope. This will help the doctors find out more about the cancer.

The pathologist will also check that the surgeon has removed the tumour together with a border of tissue that is free of cancer cells.

Patients will need a general anaesthetic for a wide local excision and will be in hospital overnight. The patient will have some pain after the surgery and his penis may be swollen for a week to 10 days.

Removal of the head of the penis (glansectomy) – one may hear this operation referred to as a glansectomy. This is because the surgeon removes the glans (head). A person might have this operation if the tumour is stage 1 or T1 or T2. The surgeon will then do a skin graft to reconstruct the head of the penis. The skin is usually taken from the thigh. After this operation the penis will look like a circumcised penis. Such a person will be able to pass urine normally and most men who were sexually active before the operation remain so after the operation.

If cancer has started to grow into the shaft of the penis, the surgeon will need to remove a bit more. The man will still have a skin graft done but the penis will be shorter. It is sometimes possible for surgeons to combine this operation with a penis lengthening operation.

Removal of the penis (penectomy) - if the cancer is large, the patient may need to have either part or all of his penis removed (partial or total penectomy). A total penectomy is only done if the cancer is deep into the penis, or is at the base of the penis.

Nowadays doctors usually do a glansectomy rather than a partial penectomy. If the person needs a partial penectomy, the surgeon will remove the end of the penis. They will aim to leave enough of the shaft of the penis behind to allow the person to pass urine standing up, with the flow of urine clear of the body.

If one needs a total penectomy the surgeon will remove the shaft and root of the penis. The root is the part which goes up inside the body. During the operation, the surgeon will form a hole between the anus and the scrotum, through which the person will pass urine. The patient will still have control over passing urine, because the muscle that keeps the bladder closed is further inside the body, above the penis.

About Clinical Trials

Clinical trials are research studies that involve people. They are conducted under controlled conditions. Only about 10% of all drugs started in human clinical trials become an approved drug.

Clinical trials include:

- Trials to test effectiveness of new treatments
- Trials to test new ways of using current treatments
- Tests new interventions that may lower the risk of developing certain types of cancers
- Tests to find new ways of screening for cancer

The [South African National Clinical Trials Register](#) provides the public with updated information on clinical trials on human participants being conducted in South Africa. The Register provides information on the purpose of the clinical trial; who can participate, where the trial is located, and contact details.

For additional information, please visit: www.sanctr.gov.za/

Medical Disclaimer

This Fact Sheet is intended to provide general information only and, as such, should not be considered as a substitute for advice, medically or otherwise, covering any specific situation. Users should seek appropriate advice before taking or refraining from taking any action in reliance on any information contained in this Fact Sheet. So far as permissible by law, the Cancer Association of South Africa (CANSAs) does not accept any liability to any person (or his/her dependants/estate/heirs) relating to the use of any information contained in this Fact Sheet.

Whilst CANSAs has taken every precaution in compiling this Fact Sheet, neither it, nor any contributor(s) to this Fact Sheet can be held responsible for any action (or the lack thereof) taken by any person or organisation wherever they shall be based, as a result, direct or otherwise, of information contained in, or accessed through, this Fact Sheet.



Sources and References consulted or Utilised

Cancer Research UK

<http://www.cancerresearchuk.org/about-cancer/type/penile-cancer/treatment/surgery/types-of-surgery-for-penile-cancer>

Chan, S.L., Watchorn, R.E., Panagou, E., Panou, E., Ong, E.L., Heelan, K., Haider, A., Freeman, A. & Bunker, C.B. 2018. Dermatoscopic findings of penile intraepithelial neoplasia: Bowenoid papulosis, Bowen disease and erythroplasia of Queyrat. *Australas J Dermatol.* 2018 Dec 25. doi: 10.1111/ajd.12981. [Epub ahead of print]

Bruni, L., Albero, G., Serrano, B., Mena, M., Gómez, D., Muñoz, J., Bosch, F.X. & de Sanjosé, S. 2019. ICO/IARC Information Centre on HPV and Cancer (*HPV Information Centre*). Human Papillomavirus and Related Diseases in South Africa. Summary Report 17 June 2019. [Date Accessed]

DermNet.NZ

<http://www.dermnetnz.org/site-age-specific/penile-intraepithelial-neoplasia.html>

Globocan

<https://gco.iarc.fr/today/data/factsheets/populations/710-south-africa-fact-sheets.pdf>

Hoekstra, R.J., Trip, E.J., Ten Kate, F.J., Horenblas, S. & Lock, M.T. 2018. Penile intraepithelial neoplasia: nomenclature, incidence and progression to malignancy in the Netherlands. *Int J Urol.* 2018 Dec 3. doi: 10.1111/iju.13871. [Epub ahead of print]

Kristiansen, S., Svensson, Å., Drevin, L., Forslund, O., Torbrand, C. & Biartling, C. 2018. Risk factors for penile intraepithelial neoplasia: a population-based register study in Sweden, 2000-2012. *Acta Derm Venereol.* 18 Nov 14. doi: 10.2340/00015555-3083. [Epub ahead of print]

Male Reproductive System

<http://www.webmd.com/men/picture-of-the-penis>

Olesen, T.B., Sand, F.L., Rasmussen, C.L., Albiéri, V., Toft, B.G., Norrild, B., Mun, K. C & Kliær S.K. 2018. Prevalence of human papillomavirus DNA and p16^{INK4a} in penile cancer and penile intraepithelial neoplasia: a systematic review and meta-analysis. *Lancet Oncol.* 2018 Dec 17. pii: S1470-2045(18)30682-X. doi: 10.1016/S1470-2045(18)30682-X. [Epub ahead of print]

Nadimi, E.E. & Hendi, A. 2018. Penile squamous cell carcinoma with urethral extension treated with Mohs micrographic surgery. *Cutis.* 2018 Apr; 101(4):E15-E18.

National Cancer Institute

<http://www.cancer.gov/about-cancer/treatment/clinical-trials/what-are-trials>

Patient.co.uk

<http://www.patient.co.uk/doctor/penile-cancer-pro>

PathologyOutlines.Com

<http://www.pathologyoutlines.com/topic/penscrotumPeIN.html>

Penile Intraepithelial Neoplasia 1

<https://www.google.co.za/search?q=penile+intraepithelial+neoplasia&biw=1517&bih=714&source=Inms&tbm=isch&sa=X&ei=SPMbVZn3D->

[WU7QabgIHIBw&sqi=2&ved=0CAYQ_AUoAQ&dpr=0.9#imgdii=_&imgrc=nzNGGgCMler5TM%253A%3BqZxXFryG_kO9TM%3Bhttp%253A%252F%252Fstatic-content.springer.com%252Fimage%252Fart%25253A10.1007%25252Fs00105-009-1873-3%252FMediaObjects%252F105_2009_1873_Fig1_HTML.jpg%3Bhttp%253A%252F%252Flink.springer.com%252Farticle%252F10.1007%252Fs00105-009-1873-3%252Ffulltext.html%3B402%3B331](http://www.springer.com/252Fstatic-content.springer.com%252Fimage%252Fart%25253A10.1007%25252Fs00105-009-1873-3%252FMediaObjects%252F105_2009_1873_Fig1_HTML.jpg%3Bhttp%253A%252F%252Flink.springer.com%252Farticle%252F10.1007%252Fs00105-009-1873-3%252Ffulltext.html%3B402%3B331)

Penile Intraepithelial Neoplasia 2

http://journals.lww.com/humanandrology/Fulltext/2013/03000/Penile_intraepithelial_neoplasia___management_and.2.a.spx

Researched and Authored by Prof Michael C Herbst

[D Litt et Phil (Health Studies); D N Ed; M Art et Scien; B A Cur; Dip Occupational Health; Dip Genetic Counselling; Diagnostic Radiographer; Dip Audiometry and Noise Measurement; Medical Ethicist]

Approved by Ms Elize Joubert, Chief Executive Officer [BA Social Work (cum laude); MA Social Work]

January 2020

Seminars in Diagnostic Pathology

<http://www.semdiagpath.com/article/S0740-2570%2811%2900108-0/abstract>

WebMD

<http://www.webmd.com/men/picture-of-the-penis>

Researched and Authored by Prof Michael C Herbst

[D Litt et Phil (Health Studies); D N Ed; M Art et Scien; B A Cur; Dip Occupational Health; Dip Genetic Counselling; Diagnostic Radiographer; Dip Audiometry and Noise Measurement; Medical Ethicist]

Approved by Ms Elize Joubert, Chief Executive Officer [BA Social Work (cum laude); MA Social Work]

January 2020